CT Scans & MRI Scans with reports

LT-RT
D12
L1
PUTTAMADAMMA Mrs . 061Y F 2054656 MRI SPINE SCREENING & TL SPINE 9/11/20

C2
D1
L1
L5
PUTTAMADAMMA Mrs . 061Y F 2054656 MRI SPINE SCREENING & TL SPINE 9/11/2019
JSS HOSPITAL

NAME	PUTTAMADAMMA	DATE	11.09.2019
AGE	61Y/Female	MRI NO	2054656
REF/DOC	RAILWAYS		
MRI SCAN OF DORSOLUMBAR SPINE + WSS			

CLINICAL HISTORY: Old fracture of D12 vertebra.

SEQUENCES: Sagittal T 1, T2 and STIR sequences; Axial T1,T2; Coronal T2 in 3T MRI.

FINDINGS:

The curvature of dorso-lumbar spine is altered. Anterior wedge compression fracture of D12 vertebral body with reduced height of vertebral body and altered signal intensities appearing hypointense on T1 & T2 and hyperintense on STIR- s/o marrow edema. There is retropulsion of fracture fragments causing canal space narrowing (9mm) and indentation of the cord at this level resulting in posterior displacement of the cord. The spinal cord at this level shows subtle signal changes appearing hyperintense on T2& STIR for a length of ~1.9cm. Rest of the dorso-lumbar vertebrae are normal in height, alignment and signal intensity. Marginal osteophytes noted at multiple levels. The pedicles, laminae, transverse processes, spinous processes and facet joints are normal.

The status of the intervertebral discs and the canal space measurements at various levels are as follows:

Level	Lateral	Comments
L5-S1	1.10cm	**Disc-osteophyte complex and diffuse posterior disc bulge with right far lateral disc herniation causing anterior thecal sac indentation & bilateral neural foraminal narrowing (right > left) resulting in indentation of right exiting nerve roots.**
L4-L5	1.25cm	Diffuse posterior disc bulge causing anterior thecal sac indentation. **Nerve roots are intact.**
L3-L4	1.29cm	**Posterior annular tear. Diffuse posterior disc bulge causing anterior thecal sac indentation. Nerve roots are intact.**
L2-L3	1.21cm	**Diffuse posterior disc bulge causing anterior thecal sac indentation. Nerve roots are intact.**
L1-L2	1.34cm	Normal
D12-L1	**1.05cm**	**Disc appears normal. However retropulsion of the fracture fragments causing canal space narrowing as described above.**
D11-D12	1.30cm	Left ligamentum flavum hypertrophy noted.
D10-D11	1.10cm	Normal
D9-D10	1.19cm	Normal
D8-D9	1.13cm	Normal

The ALL, PLL and rest of the ligamentum flava show normal signal intensity.

The spinal cord is ending at upper border of L1. The cauda equina and thecal sac are normal in signal.

Cervical spine screening: The cervical normal in height and signal intensity. No focal lesions seen in the bones. Posterior disc bulge causing anterior thecal sac indentation at C6-C7 intervertebral disc. Rest of the intervertebral discs are normal in cervical regions. The para vertebral soft tissues are normal. The paravertebral soft tissues, muscles of the neck, back, skin and subcutaneous tissues are grossly normal.

IMPRESSION:

- **Anterior wedge compression fracture of D12 vertebral body with marrow edema and retropulsion of fracture fragments causing canal space narrowing & indentation of the cord resulting in subtle cord myelomalacic changes as described.**
- **Lumbar spondylosis with disc-osteophyte complex and diffuse posterior disc bulge with right far lateral disc herniation at L5-S1 level causing indentation of right exiting nerve roots.**

DR. SACHIN P SHETTY, MD
CONSULTANT RADIOLOGIST

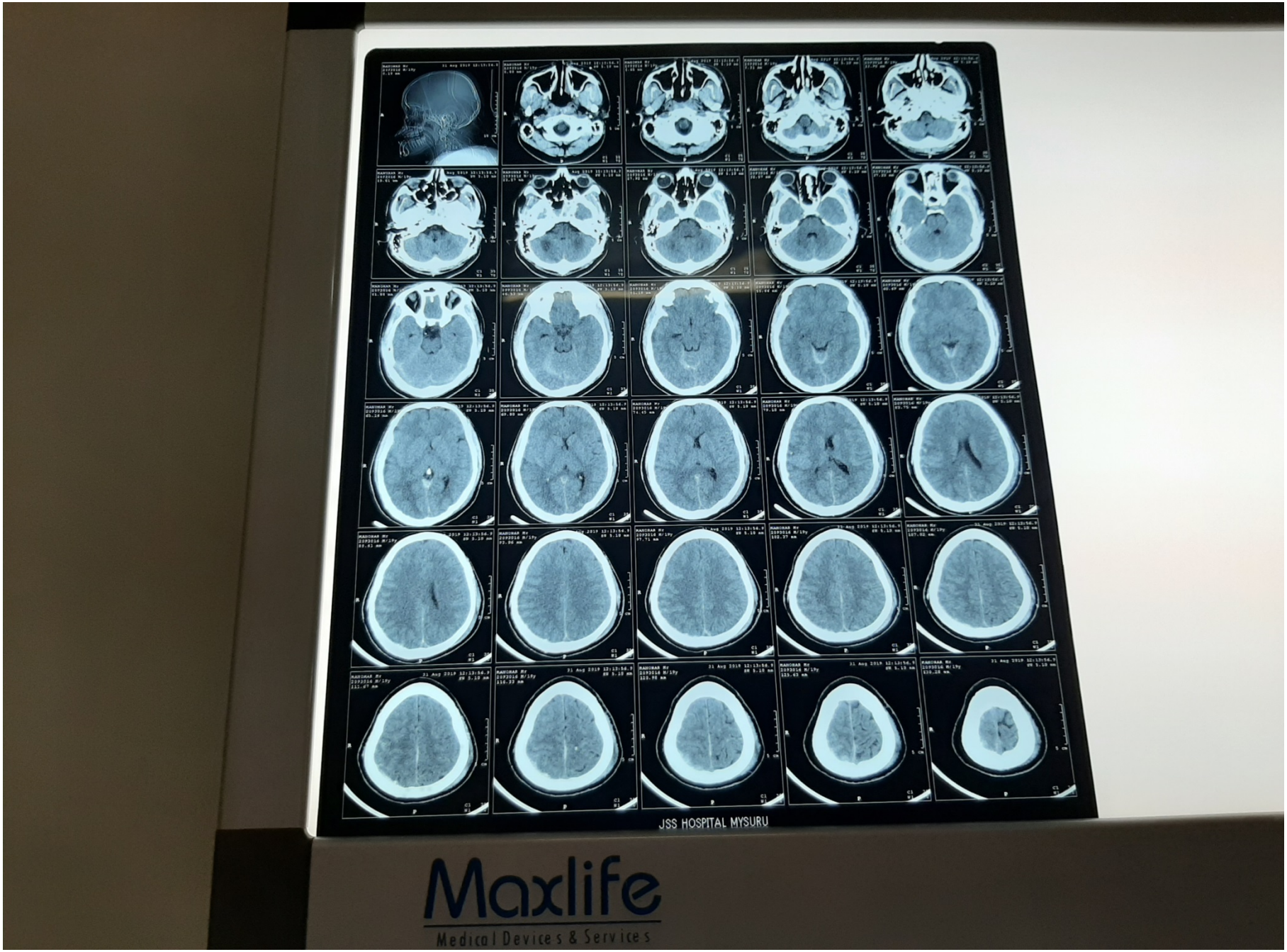
JSS HOSPITAL MYSURU
Maxlife
Medical Devices & Services

Patient Name	Mr . MANOHAR	Patient ID	2093016
Sex / Age	M / 019Yrs	Accession No.	1028556
Modality	CT	Scan Date	31-08-2019
Procedure	CT BRAIN PLAIN	Report Date/Time	31-08-2019 16:06:53
Referring Physician:DR. Col.VASAN TS			

CT SCAN OF THE HEAD

HISTORY: RTA with head injury – rib #

PROTOCOL: 5mm sections of the brain from the level of the base of the skull to the apex in 128 slice MDCT scanner.

Findings:

SDH of maximum thickness 6.4mm in the right parieto -occipital convexity.

Thin sliver of SDH is seen in right temporal convexity.

Right holohemispheric edema noted with effacement of right lateral ventricle.

Posterior interhemispheric bleed noted with extension into bilateral tentorium cerebelli.

Few hemorrhagic contusions noted in the bilateral frontal, bilateral parietal lobes and right temporal lobe with adjacent streaky SAH.

Minimal hemorrhage is seen in the occipital horn of left lateral ventricle. No evidence of significant of mid shift. Minimal pneumocephalus noted.

Rest of the Cerebral Parenchyma shows normal attenuation values.Third ventricle is normal in size and shape. No hydrocephalus. Brain stem, cerebellum and fourth ventricle are normal.

Perimesencephalic and peripontine cisterns are normal.

Fractures and soft tissue swelling as described in previous report dated 30.08.2019.

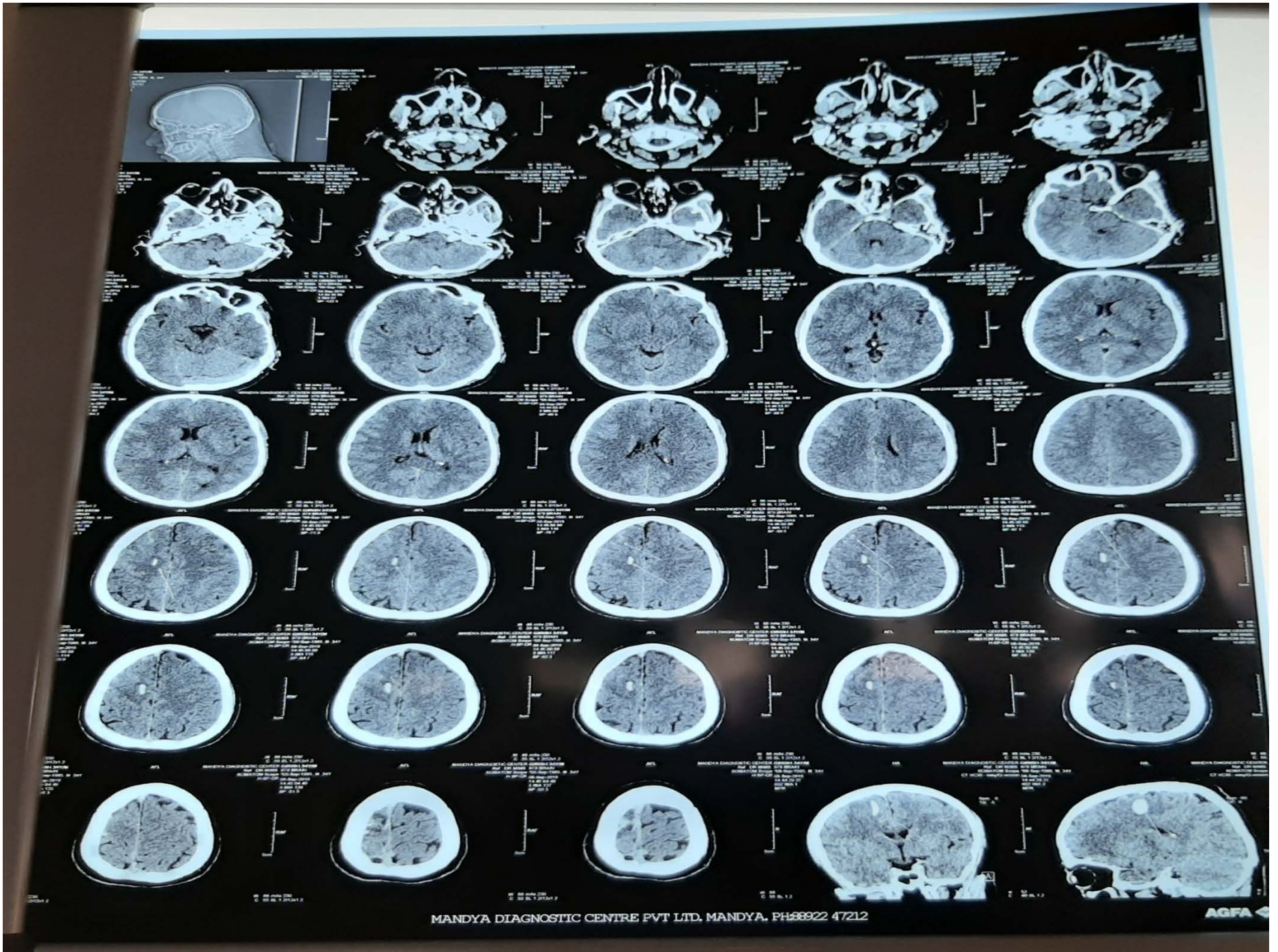
MANDYA DIAGNOSTIC CENTRE PVT LTD. MANDYA. PH:08822 47212
AGFA

Patient ID:KODA19090005423	**Patient Name**:SURESH
Age:52 Years	**Sex**:M
Accession Number:	**Modality**:CT
Referring Physician:	**Study**:01_DH_Brain_Plain(Adult)
Study Date:12-Sep-2019	

CT SCAN OF BRAIN (PLAIN)

Protocol:

Plain CT Scan of brain has been done. 5 mm thin axial sections have been obtained.

Clinical Brief: History of weakness

Observations:

Right MCA territory (frontal and periventricular) well define hypodensity noted with effacement of adjacent sulci - Suggestive of acute non hemorrhagic infarct.

Rest of cerebral hemisphere reveals normal attenuation values

Rest of basal ganglia and thalami are normal.

The sella and para sellar region appear normal.

Rest of ventricular system is normal.

The posterior fossa and its contents (Cerebellum) are normal, except promient folia

The pons and midbrain are normal.

The cisternal spaces and cortical sulci are prominent

There is no shift of the midline structures.

naa
OSTICS
ET'S DO GOOD...

Patient ID:KODA19090005423	**Patient Name**:SURESH
Age:52 Years	**Sex**:M
Accession Number:	**Modality**:CT
Referring Physician:	**Study**:01_DH_Brain_Plain(Adult)
Study Date:12-Sep-2019	

Orbits, paranasal sinus and mastoid air cells appear normal.

Bony calvarium is normal.

Old Reports Provided : YES / NO

IMPRESSION :

Right MCA territory acute non-hemorrhagic infarct

Advice: mri with diffusion

Investigations have their limitations. Solitary pathological/Radiological and other investigations never confirm the final diagnosis. They only help in diagnosing the disease in correlation to clinical symptoms and other related tests. Please interpret accordingly.

Dr. Sagar Maheshwari
M.B.B.S., D.N.B
Reg.No. 2011/05/1230

Date: 12-Sep-2019 14:15:58

can & MRI Scan Services Under PPP Mode With NHM,
ionerate Of Health, Family Welfare & Ayush Services, Karnataka
Hospital, Mysore Madikeri Road, G.T. Circle, Madikeri - 571201
200 14062
Diagnostics Pvt. Ltd. www.krsnaadiagnostics.com

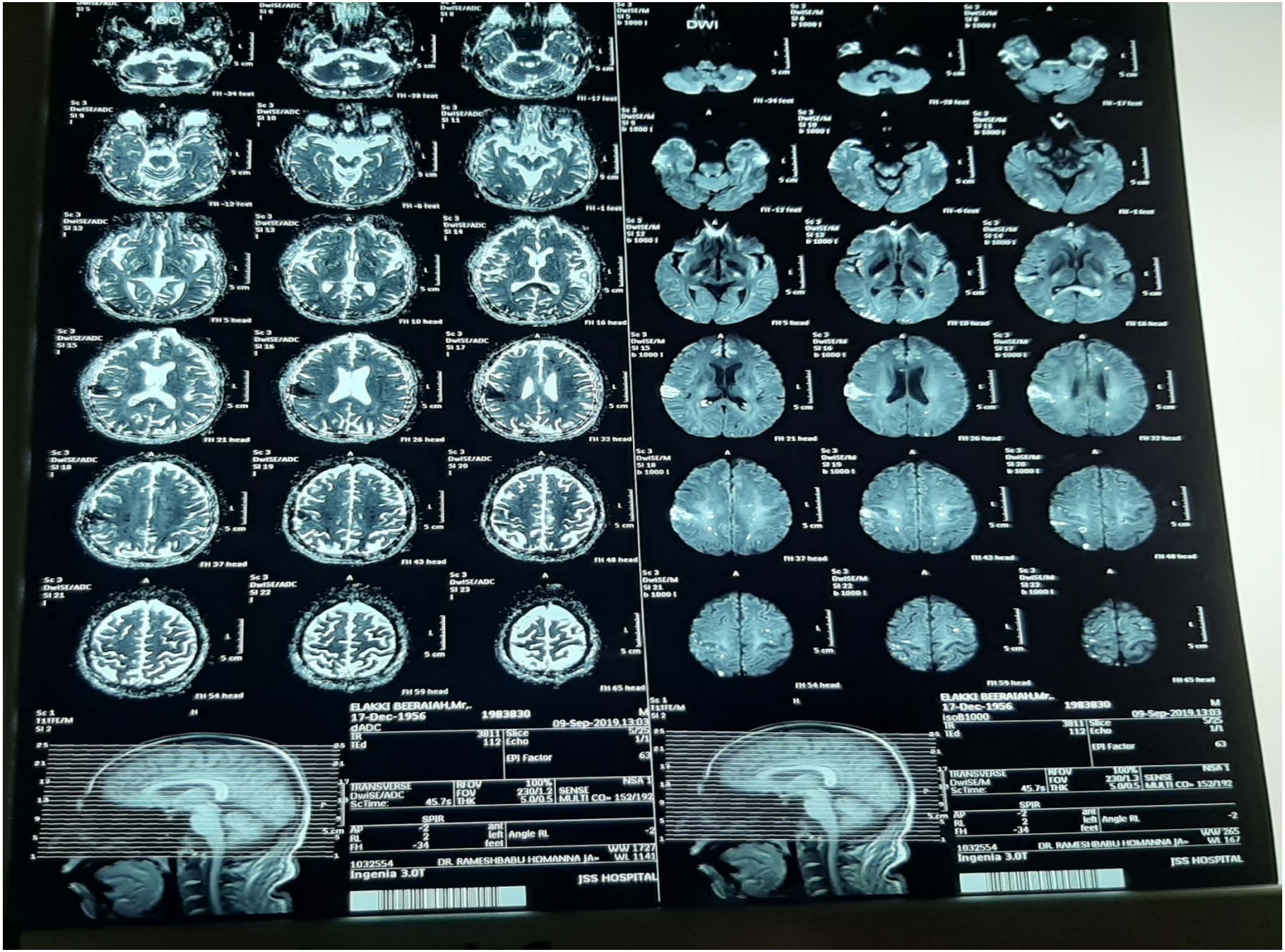
ADC
DWI
ELAKKI BEERAIAH,Mr.,
17-Dec-1956
1983830
M
09-Sep-2019,13:03
dADC
Ingenia 3.0T
JSS HOSPITAL
DR. RAMESHBABU HOMANNA JA»
1032554
ELAKKI BEERAIAH,Mr.,
17-Dec-1956
1983830
M
09-Sep-2019,13:03
isoB1000
Ingenia 3.0T
JSS HOSPITAL
DR. RAMESHBABU HOMANNA JA»
1032554

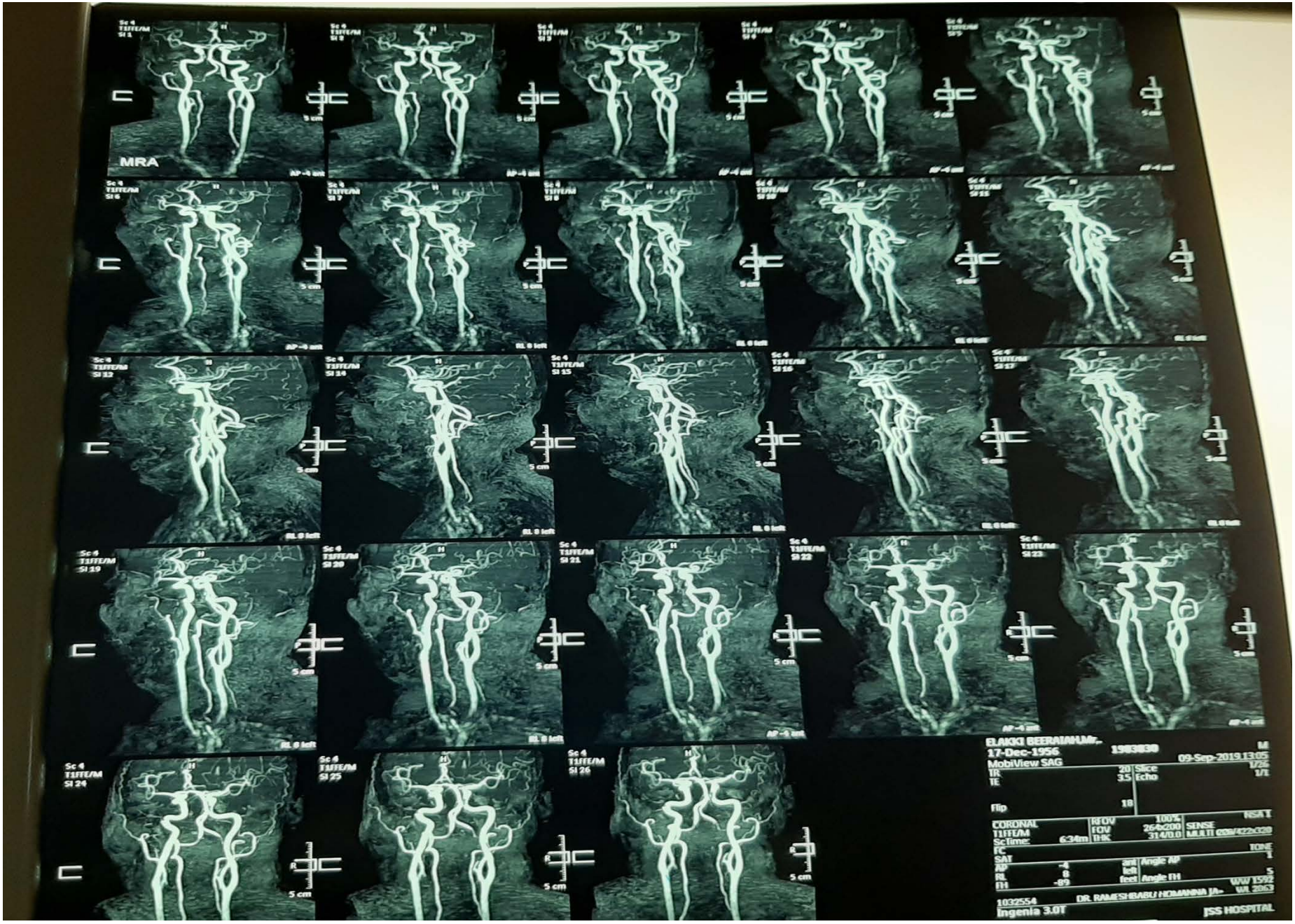
MRA
BLAKKI BEERAIAH,Mr.,
17-Dec-1956
M
1903830
09-Sep-2019 13:05
MobiView SAG
TR 20
TE 3.5
Slice 1/26
Echo 1/1
Flip 10
CORONAL
T1FFE/M
ScTime: 6:34m
RFOV 100%
FOV 264x200
BHC 314/0.0
SENSE
NSAT
FC
SAT
AP -4
RL 8
FH -89
ant
left
feet
Angle AP
Angle FH
ZOOM 1502
WL 2063
1032554
DR. RAMESHBABU HOMANNA JA-
Ingenia 3.0T
JSS HOSPITAL

JSS HOSPITAL
IN SERVICE TO LIFE

Radiology & Imaging Report

Mahatma Gandhi Road, Mysore- 570004.
Ph: 0821-2335555, Fax No: 0821-2335556
Email: contact@jsshospital.in/Website: www.jsshospital.in

Name : ELAKKI BEERAIAH	Date : 09.09.2019	Ref: JSSH
Age / Sex : 62 Y/M	IP/OP NO:1983830	MRL NO: 1983830

MRI – STROKE PROTOCOL

HISTORY: ? CVA

PROTOCOL:
Multi planner and multi sequence MRI of Brain was performed using following protocol:
AXIAL DWI, T2W and FLAIR + VEN Bold + MRA sequences in 3 T scanner.

Findings:
Multifocal acute infarcts are seen in the bilateral fronto-parieto-occipital & right temporal lobe, splenium of corpus callosum and bilateral cerebellar hemisphere. Few of the lesions show foci of blooming in the bilateral parietal lobe – s/o micro-bleed.

MRA:
MR Angiography shows normal course and caliber of intra-cranial portions of the internal carotid arteries. No intra luminal thrombus seen.

Both middle cerebral, anterior cerebral, posterior cerebral and vessels of circle of willis shows normal signal intensity. No narrowing or occlusion.

Basilar and posterior cerebral arteries are normal. No vascular malformation noted.
Both VA are normal.

IMPRESSION:

- **Multifocal acute infarct seen in the bilateral fronto-parieto-occipital & right temporal lobe, splenium of corpus callosum and left cerebellar hemisphere -? Embolic.**
- **Few of the lesions show foci of blooming in the bilateral parietal lobe - s/o micro-bleed.**

Dr. Aparna C, DMRD, DNB

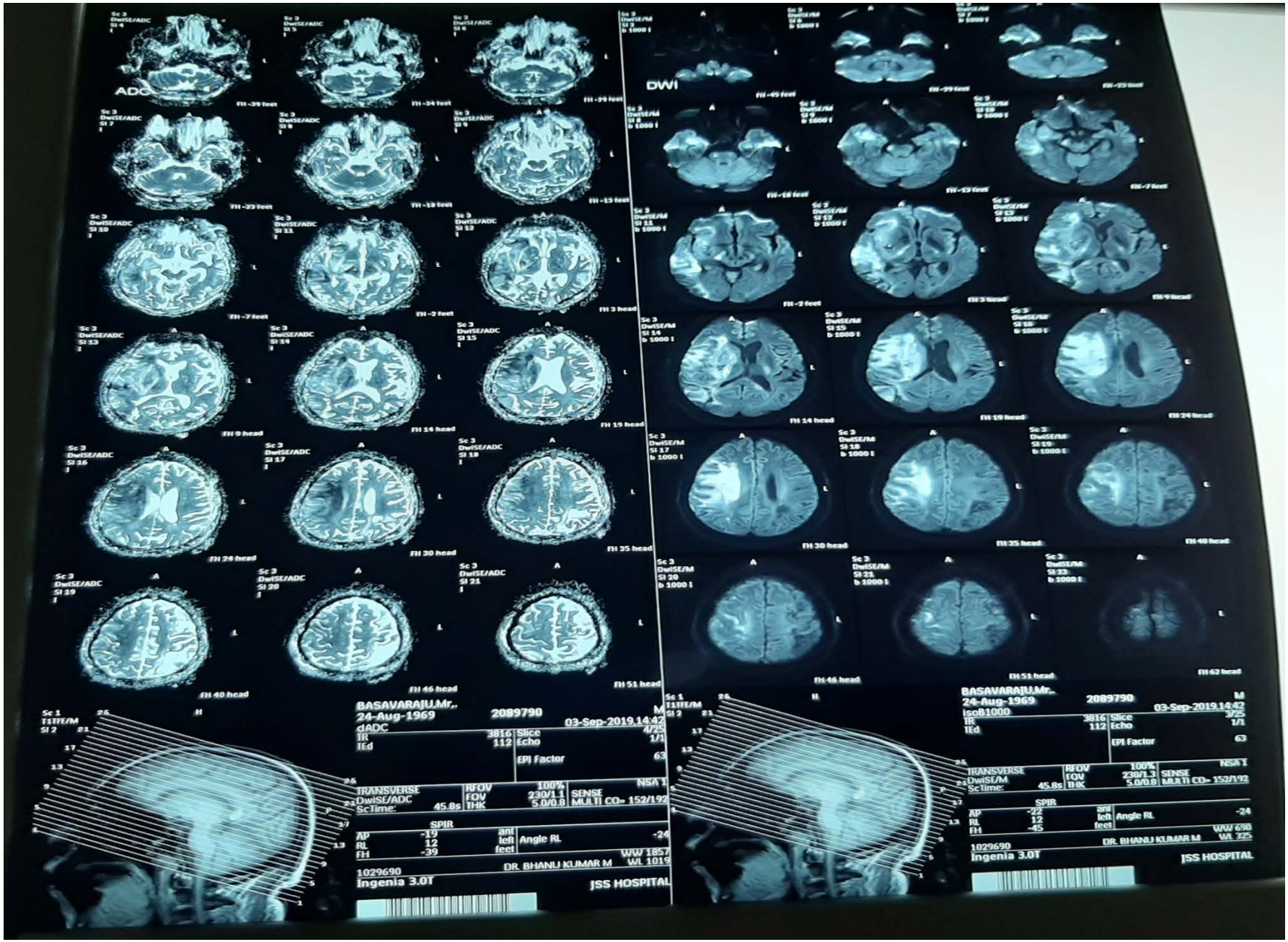
ADC
DWI
BASAVARAJU,Mr,.
24-Aug-1969
2089790
03-Sep-2019.14:42
dADC
TRANSVERSE
DwiSE/ADC
ScTime: 45.8s
RFOV 100%
FOV 230/1.1
THK 5.0/0.8
SENSE MULTI CO- 152/192
NSA 1
SPIR
AP -19
RL 12
FH -39
ant
left
feet
Angle RL -24
WW 1857
WL 1019
1029690
DR. BHANU KUMAR M
Ingenia 3.0T
JSS HOSPITAL
BASAVARAJU,Mr,.
24-Aug-1969
2089790
03-Sep-2019.14:42
isoB1000
TRANSVERSE
DwiSE/M
ScTime: 45.8s
RFOV 100%
FOV 230/1.3
THK 5.0/0.8
SENSE MULTI CO- 152/192
NSA 1
SPIR
AP -22
RL 12
FH -45
ant
left
feet
Angle RL -24
WW 698
WL 325
1029690
DR. BHANU KUMAR M
Ingenia 3.0T
JSS HOSPITAL

MRA
BASAVARAJU,Mr.,
24-Aug-1969
2089790
M
MobiView SAG
03-Sep-2019 14:46
TR 20
TE 3.5
Slice 1/26
Echo 1/1
Flip 18
CORONAL
T1FFE/M
ScTime: 4.52m
RFOV 100%
FOV 264x200/1.0
THK 314/0.0
NSAT
SENSE
MULTI
FC
SAT
TONE
AP -10
RL 18
FH -83
ant
left
feet
Angle RL
Angle FH
1029690
DR. BHANU KUMAR M
Ingenia 3.0T
JSS HOSPIT

NAME	BASAVARAJU	DATE	03-09-2019
AGE	50 Y/Male	MRI NO	2089790
REF/DOC	Dr. BHANUKUMAR	OP/IP	2089790
T2W MRI & MRA OF BRAIN			

CLINICAL HISTORY: C/o CVA – Right acute infarct with left midline shift. Now c/o unresponsiveness.

SEQUENCES: Axial T 1, T 2, DW, GRE, FLAIR + MRA sequences in 3T MRI scanner.

FINDINGS:

Supra tentorial region:

Acute infarcts seen in the right centrum semiovale, right fronto-parieto-temporo-occipital lobes and right capsulo-ganglionic regions with few areas of blooming in capsulo-ganglionic region causing mass effect in the form of effacement of ipsilateral lateral ventricle and leftward midline shift of 4mm.

Chronic infarct with gliotic changes noted in the left fronto-parietal lobes and left cerebellar hemisphere with few areas of blooming.

The thalami, left caudate and left lentiform nuclei show normal signal intensity.

The corpus callosum and left internal capsule are normal in signal intensity.

Infra tentorial region:

The tentorium cerebelli, rest of the cerebellum, midbrain, pons and medulla are normal in signal intensity. The 7th and 8th nerve complexes are normal.

Extra axial spaces: The extra axial spaces are normal. The cisternal system is normal.

Ventricular system: Rest of the ventricular system is normal. No e/o ventriculomegaly.

Pituitary gland: The pituitary gland shows normal size and signal intensity.

Orbital tissues: The eye ball and the orbital soft tissues show normal signal intensity.

Scalp and the calvarium: Normal in signal intensity.

MRA:

Right ICA (cervical, petrous, cavernous & supraclinoid segments) is mildly reduced in caliber from its origin.

MR Angiography shows normal course and caliber of intra-cranial portions of left internal carotid artery.

M1& M2 segments of right MCA is relatively small in caliber. Mild paucity of M3 & M4 branches noted.

Left middle cerebral, bilateral anterior cerebral, posterior cerebral and vessels of circle of willis shows normal signal intensity.

Basilar and posterior cerebral arteries are normal. No vascular malformation noted.

Right vertebral artery is hypoplastic. Left VA is normal.

HOSPITAL
N SERVICE TO LIFE

Radiology & Imaging Report

Mahatma Gandhi Road, Mysore- 570004,
Ph: 0821-2335555. Fax No: 0821-2335556
Email: contact@jsshospital.in/Website: www.jsshospital.in

NAME	BASAVARAJU	DATE	03-09-2019
AGE	50 Y/Male	MRI NO	2089790
REF/DOC	Dr. BHANUKUMAR	OP/IP	2089790
T2W MRI & MRA OF BRAIN			

IMPRESSION:

- Acute hemorrhagic infarcts in the right centrum semiovale, right fronto-parieto-temporo-occipital lobes and right capsulo-ganglionic regions causing mass effect. No significant changes as compared to previous MRI study dated 28.08.2019.
- Chronic infarct with gliotic changes in the left fronto-parietal lobes and left cerebellar hemisphere with hemosiderin deposition.
- M1& M2 segments of right MCA is relatively small in caliber with mild paucity of M3 & M4 branches.

Dr. Nagaraj Murthy, MD
Professor, Dept. of radiology

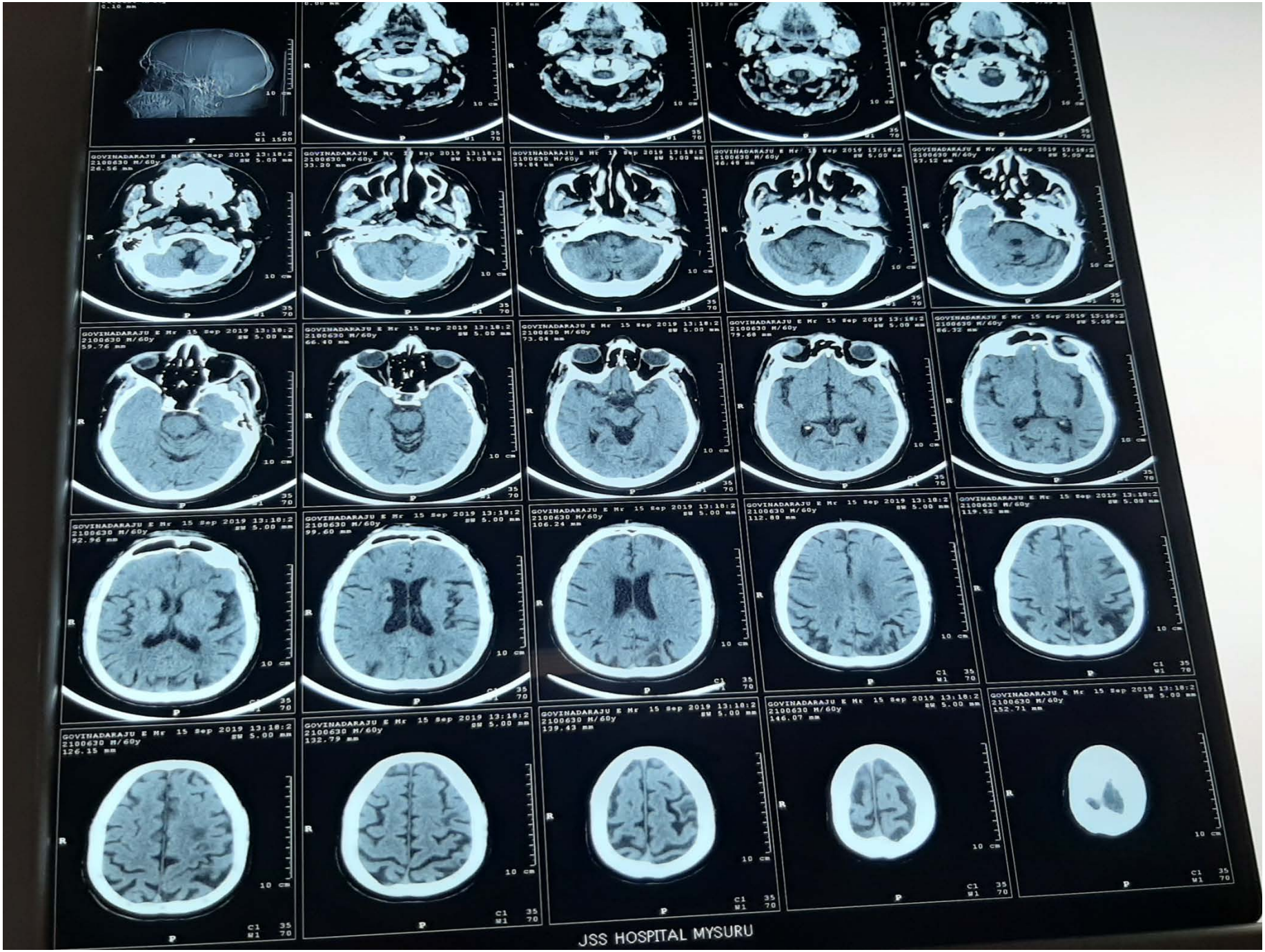
JSS HOSPITAL MYSURU

Patient Name	: Mr GOVINADARAJU E,	Age / Sender	: 60 Years / Male
Lab No	: 2100630 / IP 301451	Ward / Bed No	: EMD GREEN ZONE / [illegible]
Request No	: 776920	Referred by	: Dr HARSHA S. MBBS,MD(IM) Unit I
HOSPITAL	: 16-09-2019/10:35	Reported date and time	: 16-09-2019 / 14:57
PRECIOUS LIFE			
Diagnosis	:		

DOPPLER CAROTID

US DOPPLER CAROTID & VERTEBRAL ARTERIES

OBSERVATIONS: Both CCA and vertebral arteries shows normal color flow and normal velocity spectral waveform

RIGHT SIDE:

Arteries	PSV (cms/ sec)	EDV (cms/ sec)	PLAQUES
Right CCA	92	28	IMT-0.12 cm. Eccentric calcified plaque noted in the right carotid bulb extending in to ICA measuring 15 x 2mm (length x thickness) causing ~ 25-30% luminal narrowing with no significant hemodynamic changes.
Right ICA	134	37	IMT-0.12cm.
Right ECA	145	33	
Right Vertebral	55	22	Antegrade Flow
ICA/CCA Ratio	< 1.5		

LEFT SIDE:

Arteries	PSV (cms/ sec)	EDV (cms/ sec)	PLAQUES
Left CCA	83	17	IMT- 0.11 cm. Soft plaque noted in the left carotid bulb measuring 9.0 x 2.0mm (length x thickness) causing ~ 10-15% luminal narrowing with no significant hemodynamic changes.
Left ICA	70	35	IMT- 0.11cm.
Left ECA	124	25	
Left Vertebral	53	18	Antegrade Flow
ICA/CCA Ratio	< 1		

Other Findings: Heteroechoic solid cystic lesion measuring 18 x 25mm in right lobe of thyroid and another iso echoic solid lesion measuring 4.0 x 4.0mm in left lobe of thyroid.

IMPRESSION:
- Atherosclerotic changes in the carotid artery system.
- Eccentric calcified plaque in the right carotid bulb extending in to ICA causing ~ 25-30% luminal narrowing with no significant hemodynamic changes.
- Soft plaque in the left carotid bulb causing ~ 10-15% luminal narrowing with no significant hemodynamic changes.

Dr. Sidharthan Selvaraj
Junior Resident

R-2 (F)

DOPPLER CAROTID

Dr.VINAY RAJ R
16-09-2019 / 14:57

CT and MRI films without reports

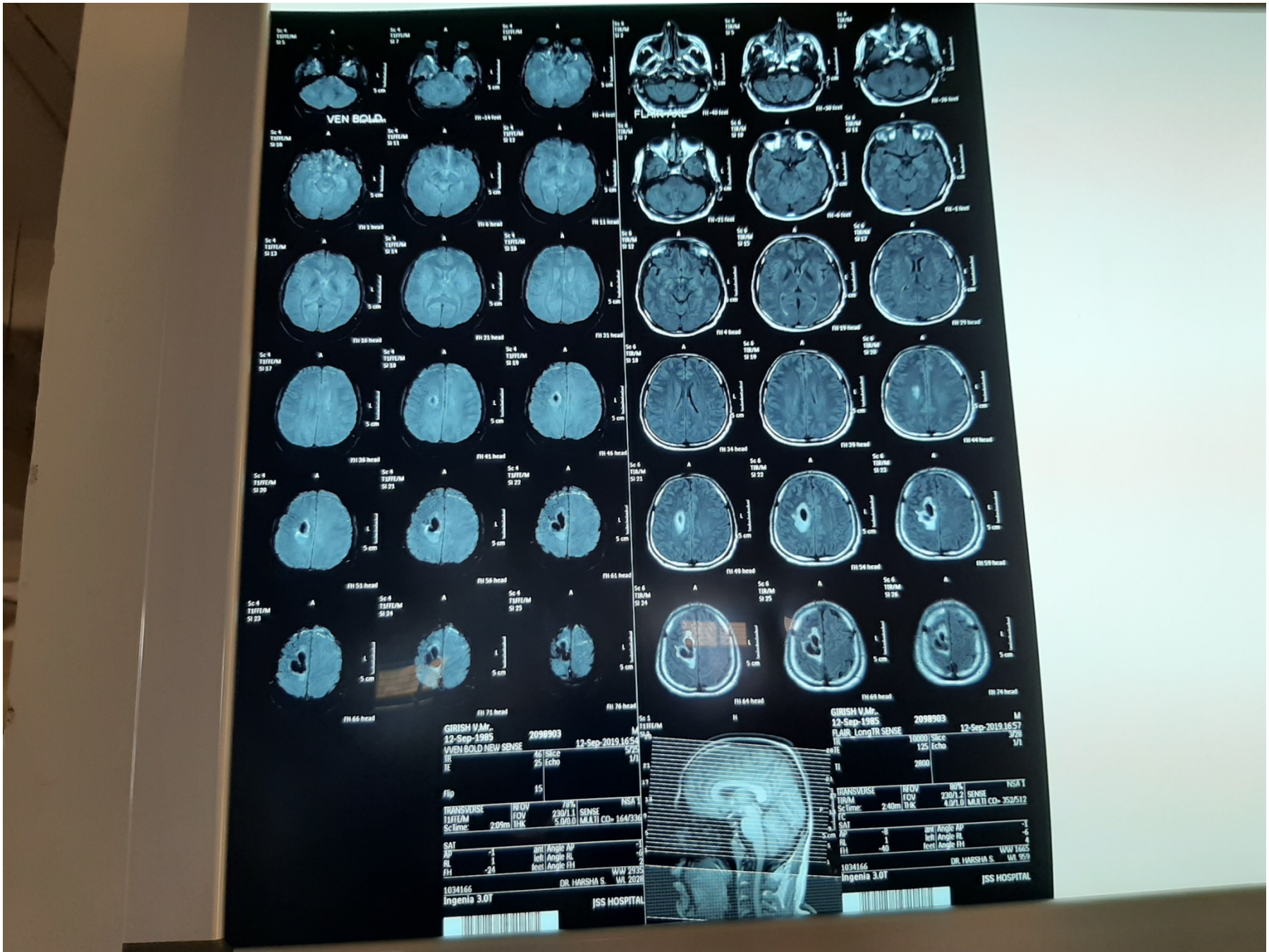
VEN BOLD
FLAIR AXIAL
GIRISH V,Mr.,
12-Sep-1985
2098903
12-Sep-2019.16:54
VVEN BOLD NEW SENSE
Ingenia 3.0T
DR. HARSHA S.
JSS HOSPITAL
GIRISH V,Mr.,
12-Sep-1985
2098903
12-Sep-2019.16:57
FLAIR_LongTR SENSE
Ingenia 3.0T
DR. HARSHA S.
JSS HOSPITAL

JSS HOSPITAL MYSURU